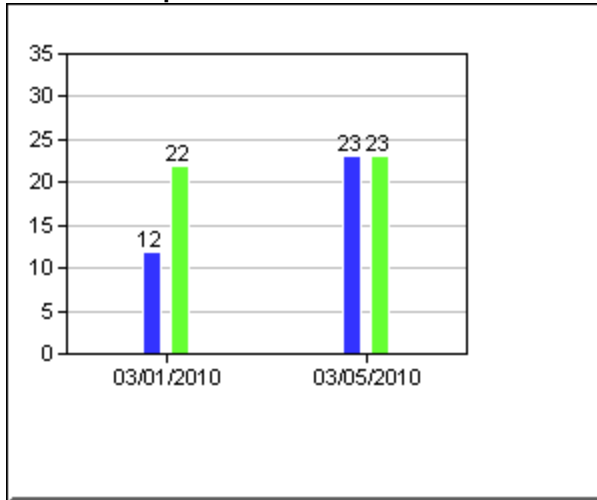
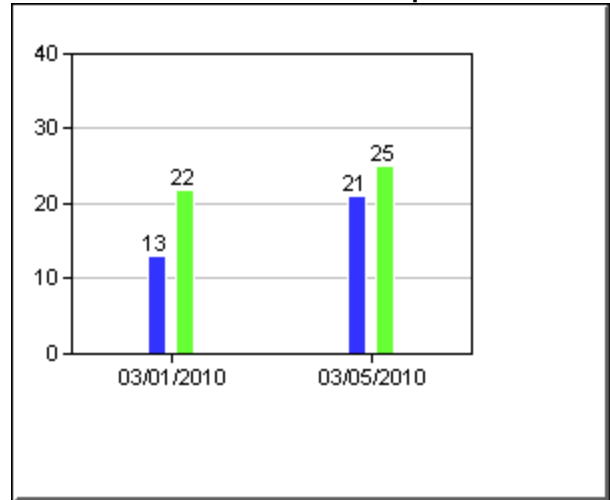


**Extensor Carpi Radialis/Ulnaris**



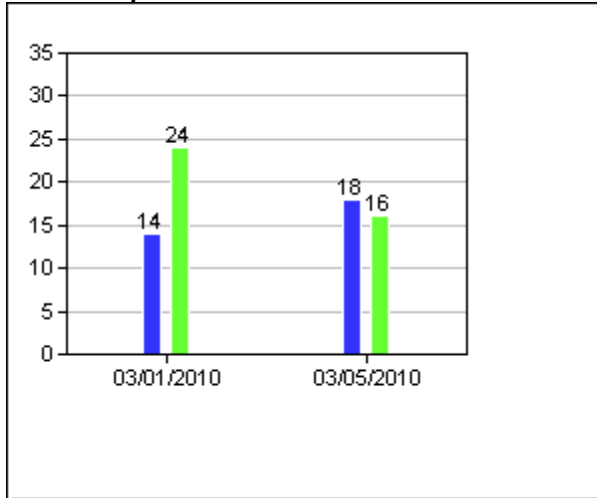
Left  
Right  
Measured with digital dynamometer

**Stemocleidoma/Scaleni/Erector Spinae**



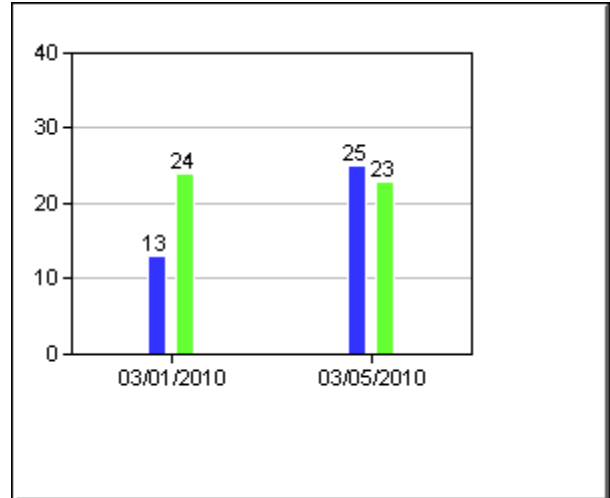
Left  
Right  
Measured with digital dynamometer

**Flexor Carpi Ulnaris**



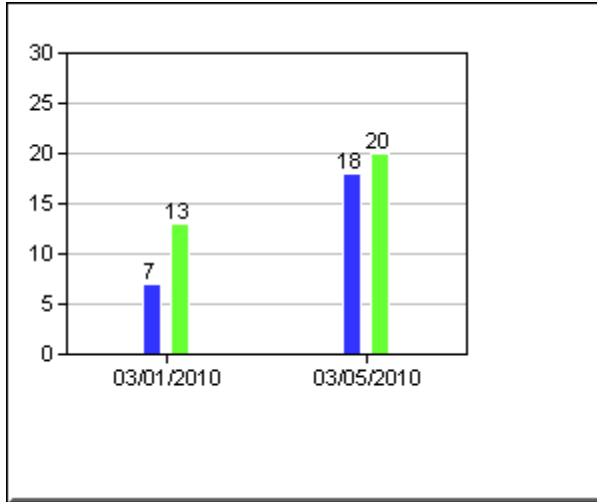
Left  
Right  
Measured with digital dynamometer

**Abductor Pollicis Brevis**



Left  
Right  
Measured with digital dynamometer

**1st Dorsal Interosseus- Index Finger**



Left

Right

Measured with digital dynamometer